

Harsukh Educational Charitable Society

International Journal of Community Health and Medical Research

Journal home page: www.ijchmr.com

doi: 10.21276/ijchmr

ISSN E: 2457-0117 ISSN P: 2581-5040

Index Copernicus ICV 2018=62.61

ORIGINAL RESEARCH

Botulinum toxin in treatment of androgenetic alopecia in males

(Col) Navtej Singh¹, (Col) Vinay Gera²

¹Department of Skin & Cosmetology, Command Hospital, Kolkata, West Bengal, India,

²Sr Adv Dermatology, Base Hospital Lucknow, U.P., India

ABSTRACT:

Background: Androgenetic alopecia is a common form of alopecia with multifactorial etiology. The present study was conducted to assess the effectiveness of botulinum toxin the cases of Androgenetic alopecia. **Materials & Methods:** The present study was conducted on 20 male patients aged 22–42 years with AGA visiting OPD. Diagnosis of AGA was based on clinical examination and trichoscopy. Botulinum toxin A 100 U was diluted in 1 mL normal saline. Insulin syringe of capacity 40 U/mL was used for injection, resulting in a concentration of 2.5 U every mark of insulin syringe. Patients were assessed periodically for improvement in their hair growth. It was graded objectively on a scale as 0, 1, 2, and 3 for poor, fair, good, and excellent. **Results:** 2 patients had poor response while 3 had fair response. No adverse effects were noted during the therapy. **Conclusion:** Authors found that botulinum toxin is an effective therapy for AGA management.

Key words: Androgenetic alopecia, baldness, botulinum toxin.

Corresponding Author: Dr. (Col) Vinay Gera, Sr Adv Dermatology, Base Hospital Lucknow, U.P., India

This article may be cited as: Singh N, Gera V. Botulinum toxin in treatment of androgenetic alopecia in males. HECS Int J Comm Health Med Res 2019; 5(2):76-78.

INTRODUCTION

Androgenetic alopecia (AGA) is the most common form of baldness characterized by progressive hair loss and affects almost 80% men in a lifetime.^{1,2} It is a multifactorial disorder caused by interactions between several genes and environmental factors. The two major genetic risk loci are the X chromosome AR/EDA2R locus and the PAX1/FOX A2 locus on chromosome 20. Recent studies indicate HAD C9 locus on chromosome 7 as a new susceptibility locus.³

The androgen receptor determines the sensitivity of cells to androgen. The AR gene regulates the potency of androgen available to the hair follicle. Of the many AR gene polymorphisms known, the Stu 1 polymorphism has the most significant association with AGA. Several other genes where associations could not be proved conclusively include 5 α reductase, aromatase, estrogen receptor α and IGF-2 genes. The role of Y chromosome needs further comprehensive examination of the genome.⁴

Botulinum toxin has been tried for AGA management once previously. Studies have found that injection of botulinum toxin relaxes the muscle, which reduces pressure on the musculocutaneous and perforating vasculature, thereby potentially increasing the blood supply and transcutaneous pO_2 . This increased blood flow can also lead to washing out of accumulated DHT, thereby reducing the signal for miniaturization of hair follicle.⁵ The present study was

conducted to assess the effectiveness of botulinum toxin the cases of Androgenetic alopecia.

MATERIALS AND METHOD

The present study was conducted in Department of Dermatology. A total of 20 male patients aged 22–42 years with AGA visiting OPD were included in the study. Diagnosis of AGA was based on clinical examination and trichoscopy. Inclusion criteria were male patients, Norwood–Hamilton grade II–IV, not treatment taken for last 6 months. Patients having history of alopecia areata, localized infection precluding injection, and neuromuscular disorders, which preclude use of botulinum toxin or any needle phobia were excluded from study. The study protocol was approved from institutional ethical committee.

General information such as name, age, gender etc. was recorded. Botulinum toxin A 100 U was diluted in 1 mL normal saline. Insulin syringe of capacity 40 U/mL was used for injection, resulting in a concentration of 2.5 U every mark of insulin syringe. In 30 different sites, 5 U was injected resulting in a total of 150 U. Injections were intramuscular and sites were selected in frontalis, occipitalis, temporalis, and periauricular muscles. Patients were assessed periodically for improvement in their hair growth. It was graded objectively on a scale as 0, 1, 2, and 3 for poor, fair, good, and excellent. Results thus obtained were subjected to statistical analysis. P value less than 0.05 was considered significant.

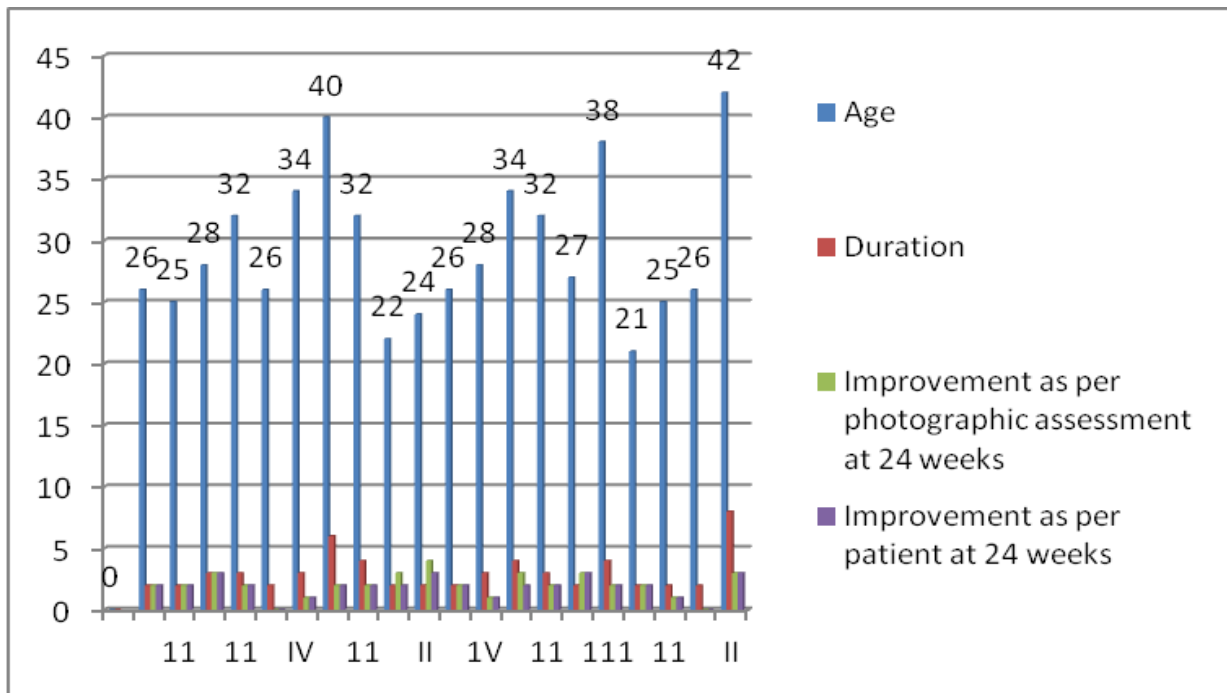
RESULTS

Table I Distribution and assessment of patients

S. No	Norwood grading alopecia	Age (years)	Duration (Years)	Improvement as per photographic assessment at 24 weeks	Improvement as per patient at 24 weeks
1	II	26	2	2	2
2	11	25	2	2	2
3	II	28	3	3	3
4	11	32	3	2	2
5	IV	26	2	0	0
6	IV	34	3	1	1
7	II	40	6	2	2
8	11	32	4	2	2
9	11	22	2	3	2
10	II	24	2	4	3
11	III	26	2	2	2
12	IV	28	3	1	1
13	111	34	4	3	2
14	11	32	3	2	2
15	11	27	2	3	3
16	111	38	4	2	2
17	111	21	2	2	2
18	11	25	2	1	1
19	IV	26	2	0	0
20	II	42	8	3	3

Table I shows that 2 patients had poor response while 3 had fair response. No adverse effects were noted during the therapy.

Graph I Distribution and assessment of patients



DISCUSSION

Androgenetic alopecia (AGA) is considered to be the most common type of baldness characterized by progressive hair loss. AGA can affect all races, but the prevalence rates vary. Prevalence is considered to be highest in Caucasians. It is estimated that prevalence rates in Caucasian populations is around 30% for men in their 30s, 40% for men in their 40s and 50% for men in their 50s.⁶

While there are different grading systems available for AGA, the most accepted is the modified Norwood-Hamilton classification [Table II], modified from the earlier Hamilton classification, consisting of seven broad groups and four specific variant types.

Class	Description
Class I	Represents an adolescent or juvenile hairline and is not actually balding. The adolescent hairline generally rests on the upper brow crease.
Class II	Indicates a progression to the adult or mature hairline that sits a finger's breadth (1.5cm) above the upper brow crease, with some temporal recession. This also does not represent balding.
Class III	The earliest stage of male hair loss. It is characterized by a deepening temporal recession.
Class III Vertex	Represents early hair loss in the crown (vertex).
Class IV	Characterized by further frontal hair loss and enlargement of vertex, but there is still a solid band of hair across the top (mid-scalp) separating front and vertex.
Class V	The bald areas in the front and crown continue to enlarge and the bridge of hair separating the two areas begins to break down.
Class VI	Occurs when the connecting bridge of hair disappears leaving a single large bald area on the front and top of the scalp. The hair on the sides of the scalp remains relatively high.
Class VII	Patients have extensive hair loss with only a wreath of hair remaining in the back and sides of the scalp.

The exact pathogenesis of male pattern baldness is not yet known. There are various causative factors implicated in causation of male pattern baldness. Orentreich⁶ proposed that minituarization of hair follicles occurs in genetically predisposed androgen-sensitive hair follicle. This androgenetic theory has been the most prevailing theory for male pattern baldness and antiandrogens such as finasteride are successfully used for the management of this condition. Transcutaneous pO_2 and blood supply before and after botulinum injection, if conducted, will also provide some insight into the pathogenesis of this common disease and mechanism of action of botulinum toxin in AGA management.⁷ Androgenetic alopecia (AGA) is one of the commonest dermatological complaints for which patients seek treatment. AGA can be a source of significant psychological distress to the affected patient. It is important for the dermatologist to understand the process of diagnosis and treatment of AGA. Though effective therapeutic options are limited, AGA continues to remain an area where expanding research is adding more information regarding pathogenesis and newer therapeutic options are being developed accordingly.⁸ Zappacosta et al⁹ in their study described treatment of male pattern baldness in patients receiving minoxidil for hypertension, and suggested topical minoxidil as an effective treatment. Few experimental studies suggested that subcutaneous blood flow in the scalp of a patient with male pattern baldness was greatly reduced as compared to controls. The implication of follicular inflammation has been brought out by several studies. The process is slow, subtle and indolent unlike the inflammatory and destructive process in the classical scarring alopecia. Microbial toxins related to Propionibacterium sp., Staphylococcus sp., Malassezia sp., or Demodex could be involved in generation of inflammatory response. Alternatively, keratinocytes may respond to chemical stress from irritants in cosmetics and grooming agents, pollutants and actinic damage as in UV irradiation by producing radical oxygen species and nitric oxide. It is characterized by progressive miniaturization of hair follicles.¹⁰ A study by Kranz¹¹ of 160 university students with AGA revealed that the psychological distress due to AGA was not dependent on the age of the patient or stage of baldness. For women affected with AGA the main factors contributing to psychological distress were - inability to style their hair, dissatisfaction with their appearance, concern about the continuing hair loss and concern about others noticing their hair loss.

The androgenetic theory states that minituarization of hair follicle results from the action of DHT. Hair follicles contain 5 α -reductase enzyme that is responsible for peripheral conversion of testosterone to more active DHT. There is an increased accumulation of DHT in the affected follicle and

disturbed DHT to estradiol ratio due to relative microvascular insufficiency, which leads to minituarization of hair follicle.¹²

CONCLUSION

Authors found that botulinum toxin is an effective therapy for AGA management, however, larger studies and controlled trial to compare it with existing FDA-approved modalities need to be conducted.

REFERENCES:

1. Tang PH, Chia HP, Cheong LL, Koh D. A community study of male androgenetic alopecia in Bishan, Singapore. Singapore Med J 2000;41:202-5.
2. Sehgal VN, Kak R, Aggarwal A, Srivastava G, Rajput P. Male pattern androgenetic alopecia in an Indian context: a perspective study. J Europ Acad Dermatol Venereol 2007;21:473-9. Back to cited text no. 2
3. Lad V, Suryawanshi C, Sinhal A, Landge A, Wagh V, Jadhav N. Androgenic alopecia: current perspectives & treatments. 2017;6(3):641-53.
4. Rathnayake D, Sinclair R. Male androgenetic alopecia. Expert Opin Pharmacother 2010;11:1295-304.
5. Freund BJ, Schwartz M. Treatment of male pattern baldness with botulinum toxin: a pilot study. Plast Reconstr Surg 2010; 126:246-8.
6. Orentreich N. Autografts in alopecias and other selected dermatological conditions. Ann N Y Acad Sci 1959;83:463-79.
7. Rathnayake D, Sinclair R. Male androgenetic alopecia. Expert Opin Pharmacother 2010; 11:1295-304.
8. Goldman BE, Fisher DM, Ringler SL. Transcutaneous PO2 of the scalp in male pattern baldness: a new piece to the puzzle. Plast Reconstr Surg 1996;97:1109-16.
9. Zappacosta AR. Reversal of baldness in patient receiving minoxidil for hypertension. N Engl J Med 1980;303:1480-1.
10. Dingman RO, Argenta LC. The surgical repair of traumatic defects of the scalp. Clin Plast Surg 1982;9:131-44.
11. Kranz D. Young men's coping with androgenetic alopecia: acceptance counts when hair gets thinner. Body Image 2011; 8:343-8.
12. Sansone-Bazzano GA, Reisner RM, Bazzano G. Conversion of testosterone-1, 23H to androstenedione-3H in the isolated hair follicle of man. J Clin Endocrinol Metabol 1972; 34:512-5.