

Original Article

Assessment Of Periodontal Health Of Abutment Teeth Supporting Removable Partial Dentures: A Retrospective Study

Ranjana Balla¹ Roshika Sudan², Himanshu Gupta²

¹Post Graduate Student, ²Reader, Department of Prosthodontics and crown& Bridge, Maharaja Ganga Singh Dental College and Research Centre, Sriganaganagar.

Abstract

Background: RPD can increase the incidence of caries; damage the periodontium, relatively large amounts of plaque and the amount of stress on natural teeth. **Aim:** To assess the periodontal health of Abutment teeth supporting Removable Partial dentures. **Materials and methods:** The present study was conducted in the Department of prosthodontics of the dental institution. We selected patients that received RPD from the department of prosthodontics. The design of the denture and classification for ridge according to Kennedy's classification (from Class I to Class IV) were recorded. For the assessment of the abutment teeth, we recorded plaque index; calculus index; bleeding on probing (BOP); probing depth (PD); gingival recession (GR); and tooth mobility (TM). **Results:** A total of 20 patients participated in the present study. 12 patients were male and 8 patients were females. The mean age of the patients was 52.23 years. Grade 0 mobility was present in majority of abutment teeth (n=27), out of which 19 teeth were with clasp retained RPDs and 6 teeth were with attachments. Gingival recession was present in 33 abutment teeth out of 45. 29 teeth were with clasp retained RPDs and 4 teeth with attachment RPDs. **Conclusion:** From the results of present study, we conclude that the periodontal health of clasp retained abutment teeth is more compromised as compared to attachment RPDs. The periodontal health can be maintained by adequate maintenance of oral and denture hygiene.

Keywords: Periodontal Ligament, Gingival Recession, Mobility, Removable Partial Denture

Corresponding author: Dr. Ranjana Balla, Post Graduate Student, Department of Prosthodontics and crown& Bridge, Maharaja Ganga Singh Dental College and Research Centre, Sriganaganagar.

This article may be cited as: Khokhar R, Sudan R, Gupta H Assessment of periodontal health of Abutment teeth supporting Removable Partial dentures: A Retrospective study. HECS Int J Com Health and Med Res 2017;3(3):56-60

INTRODUCTION

At the present time we have seen that adults with partially edentulous dentate have increased because of the increased retention of natural teeth in older adults. In this context, oral rehabilitation with removable partial dentures (RPDs) is less time-consuming and a low-cost, conservative treatment alternative in greater demand for many partially dentate patients to meet functional and esthetic needs.¹⁻³ However, longitudinal clinical studies have demonstrated periodontal alteration of abutments associated with the use of the RPD.⁴ RPD are generally attached to the abutment natural teeth by clasps or attachments that hold the denture in place. RPD in the mouth has the potential of increase plaque formation on tooth surface in contact with RPD, especially to abutment teeth, to which clasps or attachments are

attached.⁵ Epidemiological studies in animals and in humans have shown that dental plaque is an essential factor in the etiology of periodontitis.⁶ RPD can increase the incidence of caries; damage the periodontium, relatively large amounts of plaque and the amount of stress on natural teeth.⁷ Kennedy classification, denture base shape, denture construction and especially the number of position of the clasps and occlusal rests also influence periodontal deterioration.⁸ So, the present study was planned to assess the periodontal health of Abutment teeth supporting Removable Partial dentures.

MATERIALS AND METHODS

The present study was conducted in the Department of prosthodontics of the dental

institution. The ethical clearance for the protocol of study was obtained from the ethical committee of the dental institution prior to commencement of study. For the study, we selected patients that received RPD from the department of prosthodontics. They were contacted and invited to participate in the study. The duration for which the patient was wearing the removable denture following placement varied from 1 year to 7 years. For the reduction of observational error, the task of measurements was given to a single examiner. A total of 20 patients participated in the study. A written consent was obtained from the participants after explaining to them the procedure and advantages of study. The design of the denture and classification for ridge according to Kennedy’s classification (from Class I to Class IV) were recorded and noted for further evaluation.⁹ For the assessment of the abutment teeth, we recorded plaque index; calculus index; bleeding on probing (BOP); probing depth (PD); gingival recession (GR); and tooth mobility (TM). Plaque index was recorded according to Silness/ Loe Index, 1964. Calculus Index (CI) was recorded according to Green-Vermilion Index, 1964.¹⁰ Bleeding on probing (BOP) was recorded according to Ainamo & Bay, 1975. The measurement of probing depth was done using William’s probe, from crest of the gingival margin to depth of pocket. Based on the measurement, PD was graded ranging from 0-3. 0 signifies normal PD (≤ 2 mm); 1 signifies PD=2-3 mm; 2 signifies PD= 3-5 mm; 3 signifies P<5 mm. GR was measured as absent or present. The recording of tooth mobility was done according to Miller (grade 0-3). Grade 0 signifies no mobility; grade 1 signifies 1mm in horizontal; grade 2 signifies >1 mm in horizontal direction; and grade 3 signifies mobility in apical direction.^{11, 12, 13} The statistical analysis of the data was done using SPSS software version 20.0 for windows. Student’s t-test and Chi-square test were used to verify the statistical significance of the data. P value less than 0.05 was considered to be statistically analysis.

RESULTS

A total of 20 patients participated in the present study. 12 patients were male and 8 patients were females. The mean age of the patients was 52.23 years ranging between 38-68 years. The number of removable Partial dentures examined was 45 RPDs. Based on the design of RPD, 37 RPDs were clasp retained and 8 R PDs were with attachments. **Table 1** shows the tooth mobility based on RPD design. We observed that Grade 0 mobility was

present in majority of abutment teeth (n=27), out of which 19 teeth were with clasp retained RPDs and 6 teeth were with attachments. Grade 1 mobility was present in 13 patients, 11 were clasp retained and 2 were with attachments. Grade 2, 3 and 4 mobility was absent in patients with attachment RPDs. The difference was statistically significant with p value less than 0.05 (**Fig 1**). **Table 2** shows the gingival recession based on RPD design. We observed that gingival recession was present in 33 abutment teeth out of 45. 29 teeth were with clasp retained RPDs and 4 teeth with attachment RPDs. Gingival recession was absent 12 abutment teeth out of which 8 were clasp retained and 4 with attachment. The difference was statistically significant with p value less than 0.05 (**Fig 2**).

Table 1: Tooth mobility grade based on RPD design

Grade of Tooth mobility	RPD Design		TOTAL	p-value
	Clasps	Attachments		
0	20	7	27	0.02
1	11	2	13	
2	2	-	2	
3	2	-	2	
4	1	-	1	
TOTAL	37	8	45	

Fig 1: Showing tooth mobility grade based on RPD design

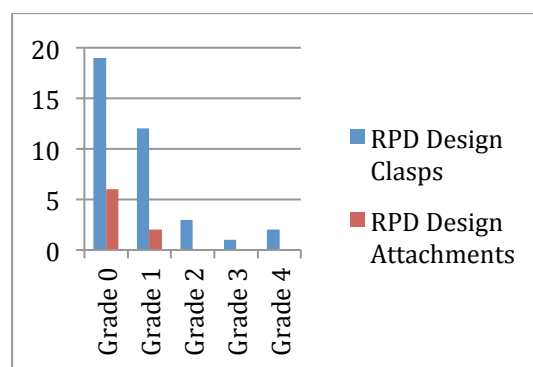
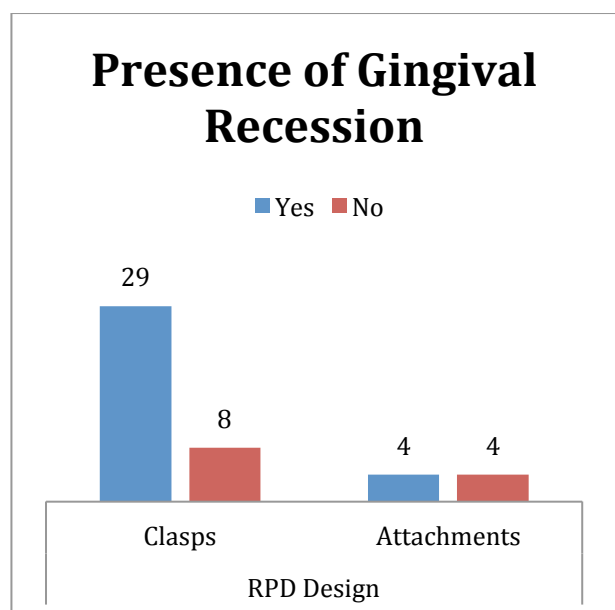


Table 2: Gingival Recession based on RPD design

Gingival Recession	RPD Design		Total	p-value
	Clasps	Attachments		
Yes	29	4	33	0.01
No	8	4	12	
TOTAL	37	8	45	

Fig 2: Showing Gingival Recession based on RPD design



DISCUSSION

The present study was conducted to assess the periodontal health of abutment teeth of Removable partial dentures. We observed that majority of abutment teeth had grade 1 mobility and gingival recession was present in these teeth. The clasp retained abutment teeth had significantly compromised periodontal health as compared to attachment RPDs. The periodontal health is evident from the gingival recession and teeth mobility. The results are consistent with other studies conducted by some authors. Tada S *et al* assessed the impact of Crown-root ratio (CRR) on the survival of abutment teeth for removable partial dentures (RPDs). Data were collected from 147 patients provided with RPDs at a dental hospital in Japan. In total, 236 clasp-retained RPDs and 856 abutment teeth were analyzed. Survival of abutment teeth was assessed using Kaplan-Meier

methods and Cox's proportional hazard (PH) regression. The Cox PH regression was used to assess the prognostic significance of initial CRR value with adjustments for clinically relevant factors, including age, sex, frequency of periodontal maintenance programs, occlusal support area, type of abutment tooth, status of endodontic treatment, and probing pocket depth. Abutment teeth were divided into 1 of 5 risk groups according to CRR: A (≤ 0.75), B (0.76-1.00), C (1.01-1.25), D (1.26-1.50) and E (≥ 1.51). The 7-year survival rate was 89.1% for group A, 85.9% for group B, 86.5% for group C, 76.9% for group D, and 46.7% for group E. The survival curves of groups A, B, and C were illustrated to be quite similar and favorable. The multivariable analysis treating CRR as a continuous variable allowed estimation of the hazard ratio at any specific CRR value. When CRR = 0.80 was set as a reference, the estimated hazard ratio was 0.58 for CRR = 0.50, 1.13 for CRR = 1.00, 1.35 for CRR = 1.25, 1.53 for CRR = 1.50, or 1.95 for CRR = 2.00. Amaral BA *et al* evaluated the periodontal conditions of removable partial denture (RPD) wearers, comparing direct and indirect abutment teeth, and the teeth not involved in the denture design before denture placement and 1 year later. Fifty patients (32 women and 18 men), average age 45, were assessed by the same examiner at the moment of denture insertion and 3, 6, 9 and 12 months later. The following items were verified in each assessment: probing depth (PD), plaque index (PI) and gingival index (GI). PD and PI data were evaluated by anova test for linear trend followed by Tukey-Kramer post-test, while GI data were analysed by Friedman's test. Results showed that the teeth not involved in the denture design were the least affected for all variables studied. It was also verified that PD and GI mean values increased from the initial assessment to 1 year of RPD wearing in every group, but that only PI showed a significant increase. This study indicated that direct and indirect retainer elements tend to undergo more damaging periodontal effects associated with RPD wearing when compared with non-abutment elements. Plaque index values were significantly higher after 1 year of denture use.^{14, 15} Akaltan F *et al* conducted a 30-month follow-up study on 36 patients to evaluate the effects of the lingual plate as a major connector in distally extended removable partial dentures (RPDs) on tooth stabilization. At the same time, the study evaluated the effects of lingual plate-type RPDs and lingual bar-type RPDs on periodontal health. The most striking finding of the study was that,

with the exception of gingival recession (GR), periodontal conditions improved with both types of RPDs. At the end of 30 months, there were significant differences in plaque index, GR and tooth mobility (TM) values between treatment groups ($P < 0.05$). Plaque accumulation was greater in the lingual plate treatment group; however, this did not result in periodontal breakdown. There were no statistically significant differences between treatment groups with respect to pocket depth, gingival index or attachment loss. Moreover, patients treated with lingual plate-type RPDs demonstrated less TM when compared with patients treated with lingual bar-type RPDs at the end of 30 months follow-up. Overall study findings established that with adequate checks on oral and denture hygiene at regular intervals, patients with RPDs may even experience improved periodontal health. Moreover, the clinical interpretation of decreased TM observed in patients treated with lingual plate-type RPDs may be questionable as the plaque accumulation was greater in the lingual plate treatment group inspite of periodic recalls. da Fonte Porto Carreiro A *et al* evaluated the periodontal conditions and integrity of abutment and non-abutment teeth of patients evaluated 7 years after insertion of the removable partial denture (RPD). Twenty-two patients (17 women, 5 men) were assessed at the moment of denture insertion and 7 years later. The following items were verified in each assessment: bleeding on probing (BP), probing depth (PD), gingival recession (GR), and mobility (M), comparing direct and indirect abutment teeth, and the teeth not involved in the denture design. Tooth integrity was also evaluated and classified as intact when no caries or fractures were observed. The Kruskal-Wallis test was used to reveal statistical significance between the groups ($p = 0.05$) as well as the Bonferroni-corrected Mann-Whitney test for post hoc comparison. Statistically significant differences were found for GR and PD between the three groups at baseline and after 7 years of follow-up. Mean BP and M values increased from initial assessment to after 7 years of RPD use in every group, but no statistically significant difference was found between the groups. For abutment integrity, a statistically significant difference was observed, and the direct abutment exhibited more caries and fractures. The authors concluded that RPDs generated more periodontal damage to direct abutments, since higher gingival recession probing depth indexes, and presence of caries and fractures were observed in comparison to indirect abutments and non-abutments.^{16, 17}

CONCLUSION

From the results of present study, we conclude that the periodontal health of clasp retained abutment teeth is more compromised as compared to attachment RPDs. The periodontal health can be maintained by adequate maintenance of oral and denture hygiene.

REFERENCES

1. Petersen PE, Yamamoto T: Improving the oral health of older people: the approach of the WHO Global Oral Health Programme. *Community Dent Oral Epidemiol* 2005;33:81-92
2. Ueno M, Ohara S, Inoue M, *et al*: Association between education level and dentition status in Japanese adults: Japan public health center-based oral health study. *Community Dent Oral Epidemiol* 2012;40:481-487
3. Douglass CW, Watson AJ: Future needs for fixed and removable partial dentures in the United States. *J Prosthet Dent* 2002;87:9-14
4. Petridis H, Hempton TJ: Periodontal considerations in removable partial denture treatment: a review of the literature. *Int J Prosthodont* 2001;14:164-172.
5. Vacaru R, Podariu AC, Jumanca D, Galuscan A, Muntean R. Periodontal-restorative interrelationships. *Oral Health Dent Med Bas Sci* 2003;3:12-5.
6. Davenport JC, Basker RM, Heath JR, Ralph JB, Glantz PO. A clinical guide to removable partial dentures. The removable partial denture equation. *Br Dent J* 2000;189:414-24.
7. Sesma N, Laganá DC, Morimoto S, Gil C. Effect of denture surface glazing on denture plaque formation. *Braz Dent J* 2005;16:129-34.
8. Davenport JC, Basker RM, Heath JR, Ralph JB, Glantz PO, Hammond P. A clinical guide to removable partial dentures. Connectors. *Br Dent J* 2001;190:184-91.
9. Phoenix RD, Cagna DR, Charles F. Stewart's: *Clinical Removable Partial Prosthodontics*. DeFreest. 4th ed. 2008.
10. Ainamo J, Bay I. Problems and proposals for recording gingivitis and plaque. *Int Dental J* 1975; 25: 229-35.
11. Mombelli A. Clinical parameters: biological validity and clinical utility. *Periodontol* 2000 2005; 39: 30-9.

12. Baker DL, Seymour GJ. The possible pathogenesis of gingival recession. A histological study of induced recession in the rat. *J Clin Periodontol* 1976; 3: 208-19.
 13. Silness J, L oe H. Periodontal disease in pregnancy correlation between oral hygiene and periodontal condition. *Acta Odont Scand* 1964; 22: 121
 14. Tada S, Allen PF, Ikebe K, Zheng H, Shintani A, Maeda Y. The Impact of the Crown-Root Ratio on Survival of Abutment Teeth for Dentures. *J Dent Res*. 2015 Sep;94(9 Suppl):220S-5S.
 15. Amaral BA, Barreto AO, Gomes Seabra E, Roncalli AG, da Fonte Porto Carreiro A, de Almeida EO. A clinical follow-up study of the periodontal conditions of RPD abutment and non-abutment teeth. *J Oral Rehabil*. 2010 Jul;37(7):545-52.
 16. Akaltan F, Kaynak D. An evaluation of the effects of two distal extension removable partial denture designs on tooth stabilization and periodontal health. *J Oral Rehabil*. 2005 Nov;32(11):823-9.
 17. da Fonte Porto Carreiro A, de Carvalho Dias K, Correia Lopes AL, Bastos Machado Resende CM, Luz de Aquino Martins AR. Periodontal Conditions of Abutments and Non-Abutments in Removable Partial Dentures over 7 Years of Use. *J Prosthodont*. 2016 Feb 10. doi: 10.1111/jopr.12449
- Conflict of Interest: None**
Source of Support: None

This work is licensed under CC BY:
Creative Commons Attribution 4.0 License.