

Harsukh Educational Charitable Society

International Journal of Community Health and Medical Research

Journal home page: www.ijchmr.com

doi: 10.21276/ijchmr

Official Publication of "Harsukh Educational Charitable Society" [Regd.]

ISSN: 2457-0117

RNI No. - PUNENG/2017/75049

Index Copernicus value 2016 = 52.13

Original Article

Assessment of Types and Features in Patients with Deviated Nasal Septum- A Clinical Study

Sanjeev Kumar¹, Devedra Bahadur Singh², Pankaj Kumar Mishra³, Daya Shankar Gond⁴

¹Assistant Professor,²Professor, ⁴Senior Resident, ENT, ³Professor, Community Medicine, Mayo Institute of Medical Sciences, Lucknow, U.P., India

ABSTRACT:

Background: Nasal septum deviation or deviated nasal septum (DNS) is a physical disorder of the nose, involving a displacement of the nasal septum. The present study was conducted to assess the cases of deviated nasal septum. **Materials & Methods:** The present study was conducted in the department of ENT on 230 patients. Radiological investigation involved CT scan of all patients. Parameters such as type of deviation and clinical features etc were noted. **Results:** Out of 230 patients, males were 100 and females were 130. The difference was non-significant ($P < 0.05$). Age group 11-20 years had 32 males and 40 females, 21-30 years had 33 males and 35 females, 31-40 had 25 males and 32 females and 41-50 years had 10 males and 23 females. The difference was significant ($P < 0.05$). Common complaints were nasal discharge (228), nasal obstruction (220), headache (210), sneezing (197), post nasal drip (150), snoring (177) and anosmia (165). The difference was significant ($P < 0.05$). Common type was midline (35), anterior vertical C shaped (45), posterior vertical C shaped (55), S shaped (40), horizontal spur (35) and combination (20). The difference was significant ($P < 0.05$). **Conclusion:** DNS is a common ENT complaint among young adults. A common symptom includes nasal obstruction, post nasal drip, nasal discharge, sneezing etc. Management included septoplasty.

Key words: Anosmia, Deviated nasal septum, Sneezing.

Corresponding Author: Dr. Devedra Bahadur Singh, Professor, ENT, Mayo Institute of Medical Sciences, Lucknow, U.P., India

This article may be cited as: Kumar S, Singh DB, Mishra PK, Gond DS. Assessment of Types and Features in Patients with Deviated Nasal Septum- A Clinical Study. HECS Int J Comm Health Med Res 2018;4(2):5-8.

INTRODUCTION

Nasal septum deviation or deviated nasal septum (DNS) is a physical disorder of the nose, involving a displacement of the nasal septum. Some displacement is common, affecting 80% of people, most unknowingly. Only more severe cases of a deviated septum will cause symptoms of difficulty breathing and require treatment. Symptoms of a deviated septum include infections of the sinus and sleep apnea, snoring, repetitive sneezing, facial pain, nosebleeds, difficulty with breathing and mild to severe loss of the ability to smell.¹

The nasal septum is the bone and cartilage in the nose that separates the nasal cavity into the two nostrils. The cartilage is called the quadrangular cartilage and the bones comprising the septum include the maxillary crest, vomer and the perpendicular plate of the ethmoid. Normally, the

septum lies centrally, and thus the nasal passages are symmetrical. A deviated septum is an abnormal condition in which the top of the cartilaginous ridge leans to the left or the right, causing obstruction of the affected nasal passage. The condition can result in poor drainage of the sinuses. People can also complain of difficulty breathing, headaches, bloody noses, or of sleeping disorders such as snoring or sleep apnea.²

Developmental septal deviation may occur. Patients in whom the septal cartilage has been damaged in the neonatal period and during birth can present with severe septal deviation in the absence of a history of nasal trauma. Microfractures sustained during late intrauterine life and during birth may cause weakness in the damaged side of the cartilage. The result is asymmetric bending of the cartilage toward the side of the injury, while the contralateral side

achieves dominance over time. These conclusions are supported by evidence matching the direction of septal deviation with the presentation of the fetal head in the pelvis during delivery.³ The present study was conducted to assess the cases of deviated nasal septum.

MATERIALS & METHODS

The present study was conducted in the department of ENT. It comprised of 230 patients with complaint of DNS. In all

patients clinical examination was done after obtaining written consent. Radiological investigation involved CT scan of all patients. General information such as name, age, gender etc. was recorded. Parameters such as type of deviation and clinical features etc. were recorded. Results thus obtained were subjected to statistical analysis using chi- square test. P value less than 0.05 was considered significant.

RESULTS

Table I Distribution of patients

Total- 230	
Males	Females
100	130

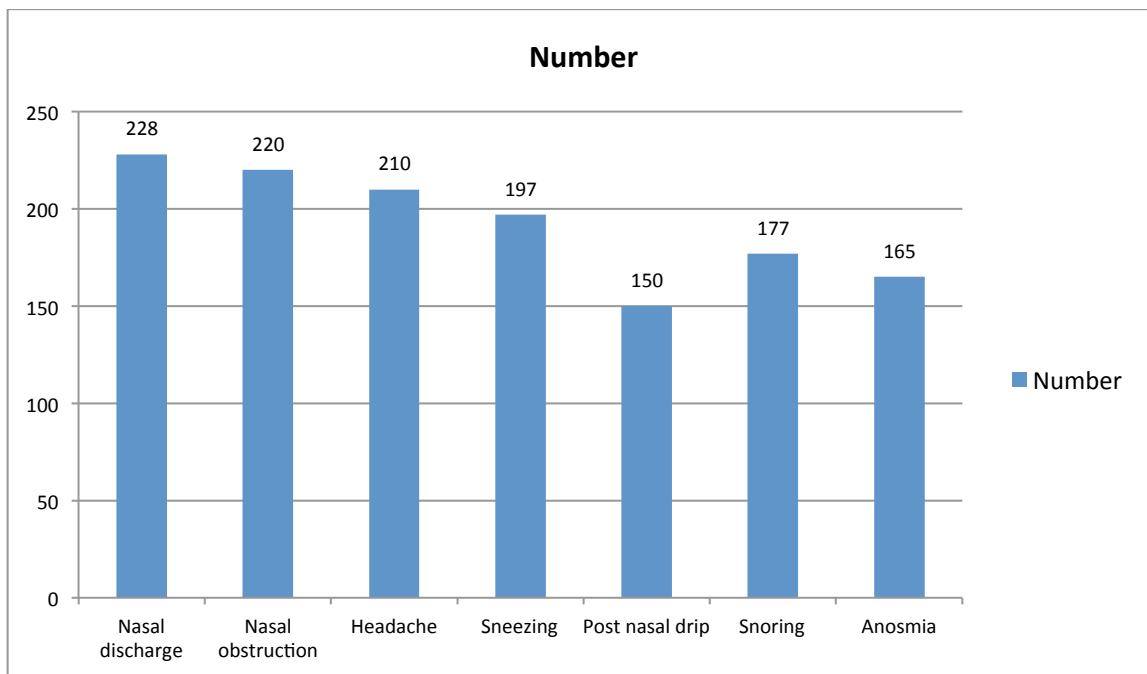
Table I shows that out of 230 patients, males were 100 and females were 130. The difference was non- significant (P- 1).

Table II Age wise distribution

Age group	Males	Females	P value
11-20	32	40	0.01
21-30	33	35	
31-40	25	32	
41-50	10	23	
Total	100	130	

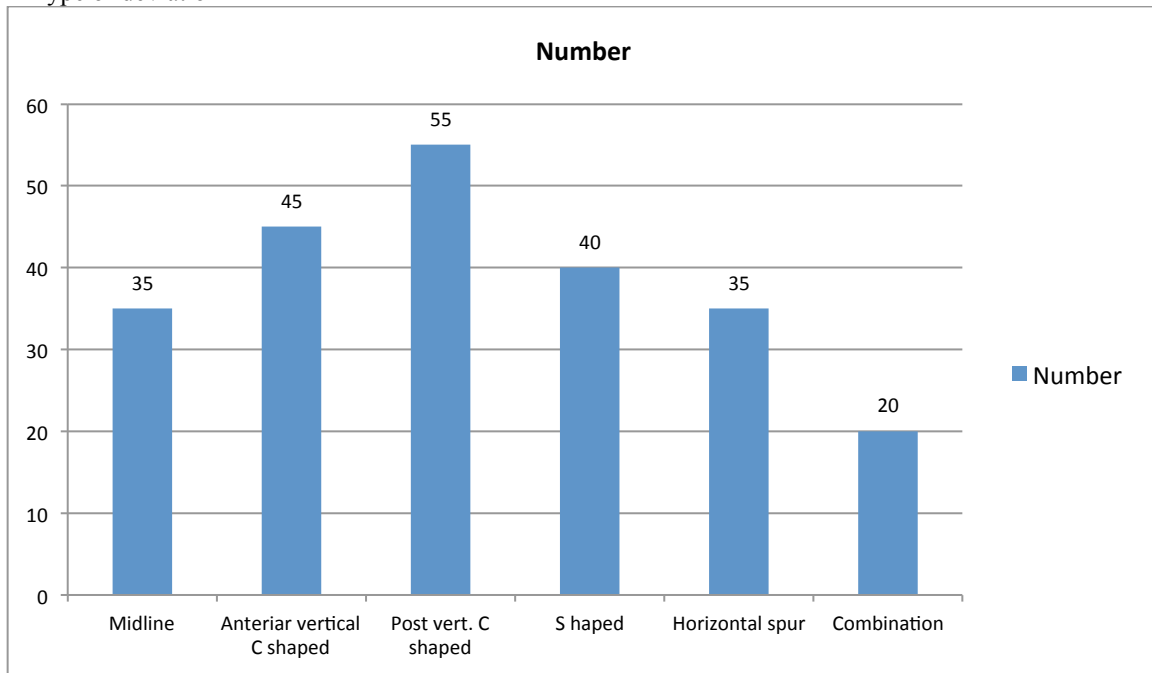
Table II shows that age group 11-20 years had 32 males and 40 females, 21-30 years had 33 males and 35 females, 31-40 had 25 males and 32 females and 41-50 years had 10 males and 23 females. The difference was significant (P< 0.05).

Graph I Complaints in patients



Graph I shows that common complaints were nasal discharge (228), nasal obstruction (220), headache (210), sneezing (197), post nasal drip (150), snoring (177) and anosmia (165). The difference was significant ($P < 0.05$).

Graph II Type of deviation



Graph II shows that common type was midline (35), anterior vertical C shaped (45), posterior vertical C shaped (55), S shaped (40), horizontal spur (35) and combination (20). The difference was significant ($P < 0.05$).

DISCUSSION

Nasal Septal deviations are extremely common, but all of them affect nasal function.¹ Many septal deviations are due to direct trauma. Incidence of Septal deviation is not known, but at our institute, surgery for correction of septal deviation is done at a rate of 300 - 350 per year and it is the second most common surgery performed after tonsillectomy. This indicates that incidence and prevalence is quite high in general population.⁴

In our study, 230 patients, males were 100 and females were 130. Age group 11-20 years had 32 males and 40 females, 21-30 years had 33 males and 35 females, 31-40 had 25 males and 32 females and 41-50 years had 10 males and 23 females. This is similar to Cantrel et al.⁵ We found that common complaints were nasal discharge, nasal obstruction, headache, sneezing, post nasal drip, snoring and anosmia.

Nasal septal deviations play a critical role in nasal obstruction symptoms, aesthetic appearance of the nose, increased nasal resistance, and sometimes snoring. Consequently, a comprehensive assessment of the nasal septum serves an essential role in preoperative planning, reestablishing function, and overall cosmetic appeal. Typically, a septoplasty suffices in addressing significant nasal septal deviations, but on occasion such deviations warrant a single-stage septorhinoplasty. In 1954, Lindahl⁶ described nasal septal deviations as either developmental (usually smooth, "C-shaped" or "S-shaped" nasal septum

with occurrence more often in the anterior septum) or traumatic (usually irregular, angulated, and sometimes dislocated) in origin. In present study, common type was midline (35), anterior vertical C shaped (45), posterior vertical C shaped (55), S shaped (40), horizontal spur (35) and combination (20).

Mladina⁷ used a similar classification system with a very precise description of the most common types of deviations seen in their practice. Mladina categorized the deviations into 7 types: Type 1: unilateral vertical septal ridge in the valve region that does not reach the valve itself, Type 2: unilateral vertical septal ridge in the valve region touching the nasal valve, Type 3: unilateral vertical ridge located more deeply in the nasal cavity, Type 4: S-shaped, Type 5: Almost horizontal septal spur, Type 6: massive unilateral bone spur, and Type 7: variation of these types. Rao⁸ also classified septal deviations into 7 types: Type I: midline septum or mild deviations in vertical or horizontal plane, Type II: anterior vertical deviation, type III: posterior vertical deviation, Type IV: S-septum, Type V: Horizontal spur on one side, Type VI: type V with a deep groove on the concave side, and Type VII: combination of II-VI.

Sharma et al⁹ in their study, a total number of 100 cases have been examined endoscopically and CT scan findings were taken. 30 cases of various grades based on Mladina classification has been chosen for the present study. In a study by Sharma et al the endoscopic findings and CT scan findings have been compared and surgery planned

accordingly. Author concluded that a standard classification of nasal septal deviation should be developed and followed so that it can be included in evaluating the symptomatology and severity of the deviated nasal septum. Thorough evaluation of deviated nasal septum by endoscopy and comparison with CT scan of paranasal sinuses is an excellent protocol to achieve significantly successful surgical outcome.

CONCLUSION

DNS is a common ENT complaint among young adults. A common symptom includes nasal obstruction, post nasal drip, nasal discharge, sneezing etc. Management included septoplasty.

REFERENCES

1. Renner G J. Management of nasal fractures. *OtolaryngolClin North Am.* 1991;24:195–213.
2. Evaluation and Reduction of Nasal Trauma, Brian P. Kelley, B.S., Cara R. Downey, M.D., and Samuel Stal, M.D. *Semin Plast Surg.* 2010; 24(4): 339–347
3. Murray J A, Maran A G. The treatment of nasal injuries by manipulation. *J Laryngol Otol.* 1980;94:1405–1410.
4. Daniel G. Becker, MD, Septoplasty and Turen Surgery. *Aesthetic surgery J* 2003; 39-103.
5. Cantrel J. Correlations of nasal symptoms and signs in random sampling study. *ActaOtolaryngal suppl.* 1974;318:1–48.
6. Lindahl: The formation of nasal septum deformation in human evolution. *Rhinology* 1977; 15: 12–20.
7. MladinaH., Fromkillian'ssubmucous septum resection and Cottle's septoplasty to modern plastic septum correction and functional septorhinoplasty, *HNO.* 1984; 32(6):230-3
8. Rao, Corti A, Bursa E, Bini A: Septal deformation in newborn infants. *Int J Pediatr Otorhinolaryngol* 1986; 11: 103–107.
9. Sharma A, Cardamakis E, Cheliodonis E, Papamihalis T: Nasal septum deformity in the newborn infant during labour. *Eur J Obstet Gynecol Reprod Biol* 1992; 44: 41–46.

Source of support: Nil

Conflict of interest: None declared

This work is licensed under CC BY: *Creative Commons Attribution 3.0 License.*