

Harsukh Educational Charitable Society

International Journal of Community Health and Medical Research

Journal home page: www.ijchmr.com

doi: 10.21276/ijchmr

Official Publication of "Harsukh Educational Charitable Society" [Regd.]

ISSN E: 2457-0117 ISSN P:2581-5040

Index Copernicus value 2016 = 52.13

Original Article

Assessment of Cases of Acute Pancreatitis - A Clinical Study

Mohd Rehan Rashid¹, Lt. Col. (Dr) Pavan Banga²

¹Associate Prof, Department of Surgery, Hind Institute of Medical Sciences, Ataria Sitapur, U.P., India ²Head of Department of Surgery, Command Hospital Lucknow, Uttar Pradesh, India

ABSTRACT:

Background: Acute pancreatitis is a common condition presenting as acute abdomen. The present study was conducted to assess patients of SAP. **Materials & Methods:** The present study was conducted on 24 cases of both genders. All were subjected to laboratory and biochemical tests such as CBC, serum LDH, serum albumin, blood glucose level, blood urea, serum creatinine, serum calcium, serum electrolytes, PaO₂ (ABG), and serum pancreatic enzymes such as amylase and/or lipase estimated. Symptoms and etiology was also recorded. **Results:** Indication for surgery was persistent MODS (8), severe sepsis (5), preoperative diagnosis (4) and suspicion of colonic involvement (7). The difference was non-significant (P= 0.01). Reason for pancreatitis was biliary pancreatitis (4), postendoscopic (9), unknown (5), and retrograde cholangiogram (6). Symptoms in patients were abdominal pain seen in 12 patients, clinical deterioration seen in 18 patients, rectal bleeding in 22 patients and asymptomatic in 2 cases. The difference was significant (P<0.05). **Conclusion:** Authors found that common reason for acute pancreatitis was postendoscopic, biliary pancreatitis and retrograde cholangiogram. Symptoms in patients were abdominal pain, clinical deterioration, rectal bleeding and asymptomatic.

Key words: Acute pancreatitis, Colonic Postendoscopic.

Corresponding author: Lt. Col. (Dr) Pavan Banga, Head of Department of Surgery, Command Hospital Lucknow, Uttar Pradesh, India

This article may be cited as: Rashid MR, Banga P. Assessment of Cases of Acute Pancreatitis - A Clinical Study. HECS Int J Comm Health Med Res 2018; 4(4):104-108

INTRODUCTION

Acute pancreatitis (AP) is defined as an inflammatory process of the pancreas with possible peripancreatic tissue and multi organ involvement inducing multi organ dysfunction syndrome (MODS) with an increased mortality rate. The incidence of acute pancreatitis per 100,000 population ranges from 5 to 80 cases per year, with the highest incidence rates being seen in Finland and the USA. Acute pancreatitis is a common condition presenting as acute abdomen.¹ This condition is broadly classified into two subtypes: one, edematous or mild acute pancreatitis and two, a necrotizing or severe acute pancreatitis. The most common symptoms and signs include severe epigastric pain (upper abdominal pain), radiating to the back in 50% of cases, nausea, vomiting, loss of appetite, fever, chills (shivering), hemodynamic instability, including shock, tachycardia (rapid heartbeat), respiratory distress, peritonitis and hiccup etc.²

While mild cases are often successfully treated with conservative measures, such as fasting and aggressive

intravenous fluid rehydration, severe cases may require admission to the intensive care unit or even surgery to deal with complications of the disease process. Accurate diagnosis of SAP on admission to the hospital is of paramount importance and there is, therefore, agreement about the need for finding predictors of severe disease to identify patients who are at risk of morbidity and death. CT findings of colonic wall thickening in patients with acute pancreatitis are mostly ignored in the daily routine as long as there is no special reason to look more actively for bowel wall lesions. This may lead to the further increase in the insult and contribute to multiorgan dysfunction syndrome (MODS) and severe sepsis. Severe acute pancreatitis implies the presence of organ failure, local complications, or pancreatic necrosis and associated disruption of the pancreatic blood supply.³ The present study was conducted to assess patients of SAP.

MATERIALS & METHOD

The present study was conducted in the department of General surgery. It comprised 26 cases of both genders (males- 12, females- 14). All were informed regarding the study and written consent was obtained. Ethical clearance was taken from institutional ethical committee.

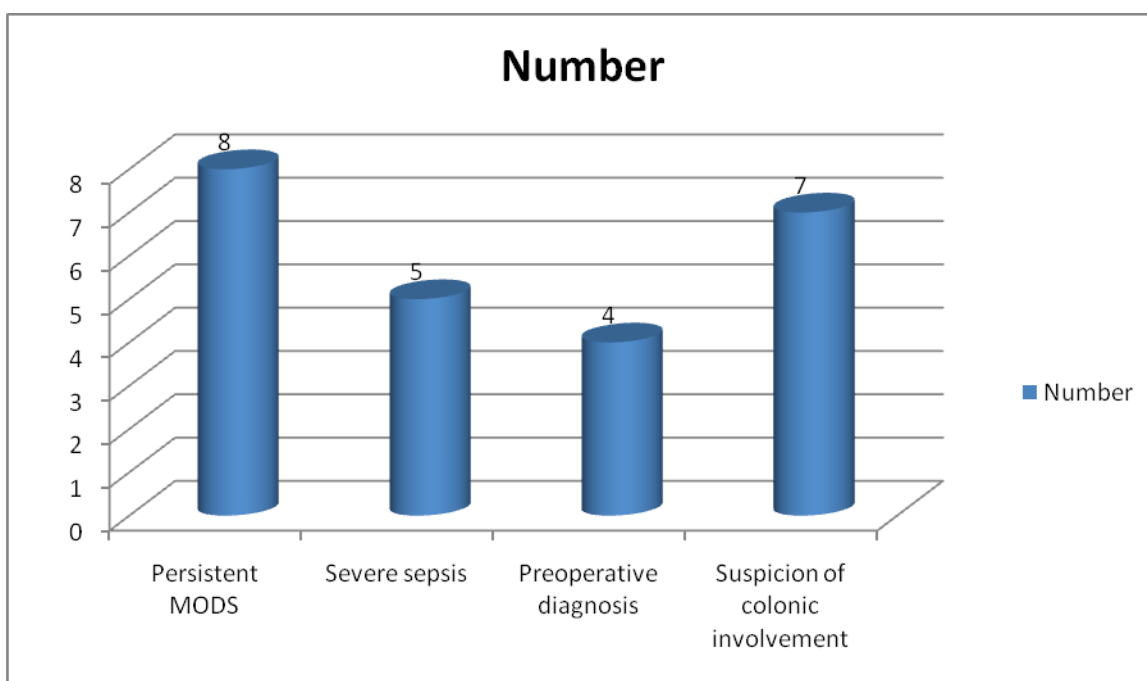
General information such as name, age, gender etc. was noted. All were subjected to laboratory and biochemical tests such as CBC, serum LDH, serum albumin, blood glucose level, blood urea, serum creatinine, serum calcium, serum electrolytes, PaO2 (ABG), and serum pancreatic enzymes such as amylase and/or lipase estimated. Contrast Enhanced Computed Tomography (CECT) was done after

72 hours to assess pancreatic necrosis, if the condition of the patient deteriorates. CT identification of local complications, particularly necrosis, is critical because patients with infected and sterile necrosis are at greatest risk of mortality.

Based on the inspection of outer aspect of the colon, patients underwent subtotal colectomy and ileostomy for suspected imminent or overt perforation, The diagnosis of ischemia was made on the basis of whether the color of the bowel wall demonstrated ischemia or hemorrhagic infarction or pulsations of the mesocolic vessels could not be palpated. Results were subjected to statistical analysis. P value < 0.05 was considered significant.

RESULTS

Graph I Indication for surgery



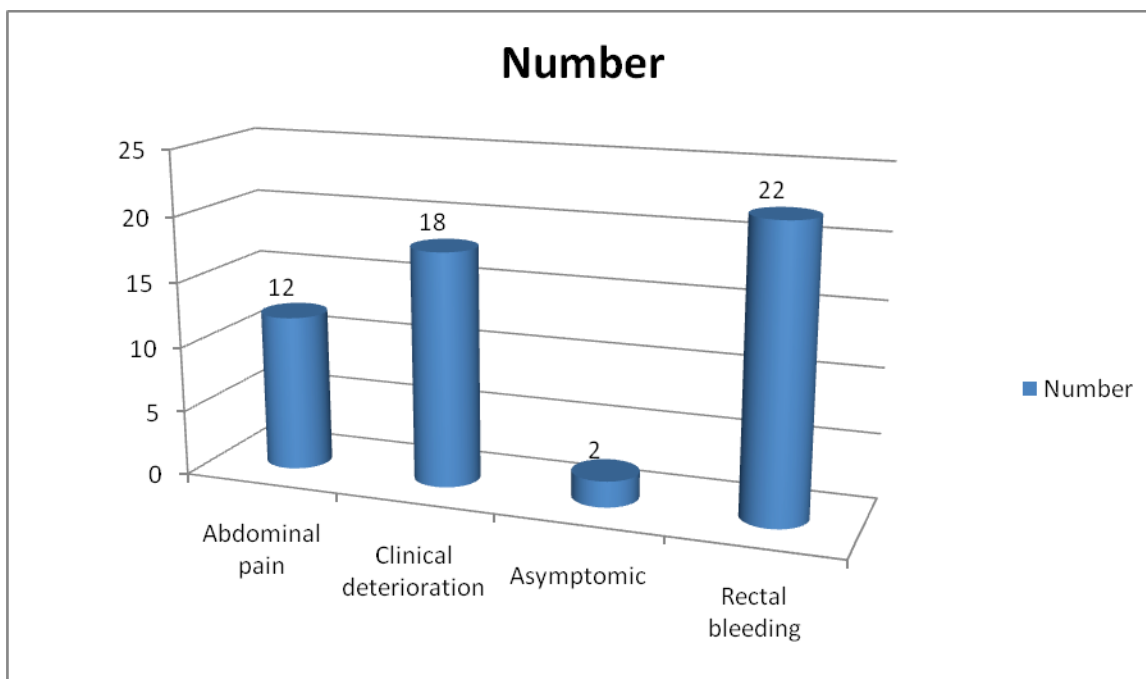
Graph I shows that indication for surgery was persistent MODS (8), severe sepsis (5), preoperative diagnosis (4) and suspicion of colonic involvement (7). The difference was non- significant (P- 0.01).

Table I Etiology of Pancreatitis

Causes	Number	P value
Biliary pancreatitis	4	0.01
Postendoscopic	9	
Unknown	5	
Retrograde Cholangiogram	6	

Table I shows that reason for pancreatitis was biliary pancreatitis (4), postendoscopic (9), unknown (5), and retrograde cholangiogram (6). The difference was significant (P<0.05).

Graph II Clinical features



Graph II shows that symptoms in patients were abdominal pain seen in 12 patients, clinical deterioration seen in 18 patients, rectal bleeding in 22 patients and asymptomatic in 2 cases. The difference was significant ($P < 0.05$).

DISCUSSION

The majority of patients have mild interstitial edematous pancreatitis (IOP) which is self-limiting. However 20% have severe acute pancreatitis (SAP) which can progress to a systemic inflammatory response syndrome (SIRS) and result in septic systemic complications with significant morbidity and mortality. Acute pancreatitis is a disease triggered by the abnormal activation of pancreatic enzymes and the release of a number of inflammatory mediators, whose etiology corresponds in about 80% of the cases to lithiasic biliary disease or excessive alcohol intake. Most of the time, it is self-limited to the pancreas and with minimal systemic effects. This mild form is characterized by presenting good clinical outcome and lower mortality rates.⁴

It can have severe complications and high mortality despite treatment. Several prognostic markers have been developed for severity stratification in acute pancreatitis. Multifactorial scoring systems incorporating clinical and biochemical criteria for severity assessment have been in use for some decades. These include the 11 criteria described by Ranson et al.⁵ in the 1970s the Glasgow score (eight criteria), MOSS score (12 criteria), BISAP score (5 criteria) and the acute physiology and chronic health evaluation (APACHE II) score (14 criteria). The present study was conducted to assess patients of SAP.

We observed that indication for surgery was persistent MODS, severe sepsis, preoperative diagnosis and suspicion

of colonic involvement. We found that reason for pancreatitis was biliary pancreatitis (4), postendoscopic (9), unknown (5), and retrograde cholangiogram (6). This is in agreement with Borie et al.⁶

Maintaining adequate intravascular volume in severe acute pancreatitis require 5 to 10 litres of IV daily for the first several days. A Swan-Ganz catheter is used to measure central venous pressure. Aggressive fluid resuscitation may not prevent pancreatic necrosis. Hemodilution to a hematocrit value of 30% with dextran 60 solution improved the pancreatic oxygenation and microcirculation and. When the hematocrit decreased to 25%, packed red blood cells should be transfused to maintain a hematocrit close to 30%.⁷

We observed that symptoms in patients were abdominal pain seen in 12 patients, clinical deterioration seen in 18 patients, rectal bleeding in 22 patients and asymptomatic in 2 cases. This is in agreement with Santos et al.⁸ Anubhav H K⁹ found that 14 were graded as severe acute pancreatitis out of 50 cases. Pancreatic necrosis was present in 15 patients, persistent organ failure in 14 cases. The AUC for modified CTSI was consistently the highest for predicting severe acute pancreatitis (0.919), pancreatic necrosis (0.993), organ failure (0.893) and ICU admission (0.993). APACHE II was the second most accurate in predicting severe acute pancreatitis (AUC 0.834) and organ failure (0.831). APACHE II had a high sensitivity for predicting pancreatic necrosis (93.33%), organ failure (92.86%) and

ICU admission (92.31%), and also had a high negative predictive value for predicting pancreatic necrosis (96.15%), organ failure (96.15%) and ICU admission (95.83%).

Bezwada et al¹⁰ found that the most common etiology in patients with acute pancreatitis was alcohol intake followed by gall stones. Chand et al¹¹ in their study of evaluation of the outcome of acute pancreatitis by Ranson's Criteria and modified CT Severity Index found ascites was the most common complication with 34.4 % patients, pleural effusion in 19.14%, pseudocyst in 10.6%), infected pancreatic necrosis 8.51% patients, and Paralytic ileus in 6.38 % patients.

CONCLUSION

Authors found that common reason for acute pancreatitis was postendoscopic, biliary pancreatitis and retrograde cholangiogram. Symptoms in patients were abdominal pain, clinical deterioration, rectal bleeding and asymptomatic.

REFERENCES

1. Gardner A, Gardner G, Feller E. Severe colonic complications of pancreatic disease. *J Clin Gastroenterol.* 2003; 37: 258–262.
2. Van Minnen LP, Besselink MGH, Bosscha K, Van Leeuwen MS, Schipper MEI, Gooszen HG. Colonic involvement in acute pancreatitis: a retrospective study of 16 patients. *Dig Surg* 2004; 21:33–40.
3. Srivastava DN, Gulati MS, Tandon RK. Colonic infarction in acute pancreatitis: an unusual cause of gastrointestinal hemorrhage. *Am J Gastroenterol* 1998; 93:1186–1187.
4. Howell DA, Dy RM, Gerstein WH et al. Infected pancreatic pseudocyst with colonic fistula successfully managed by endoscopic drainage alone: report of 2 cases. *Am J Gastroenterol* 2000; 95:1821–1822.
5. Renscon, Sikora SS, Kumar A, Kapoor VK, Saxena R, Kaushik SP. Colonic necrosis is an adverse prognostic factor in pancreatic necrosis. *Br J Surg.* 1995; 82:109–110.
6. Borie D, Frileux P, Tiret E, Berger A, Wind P, Levy E, Nordlinger B, Cugnenc PH, Parc R Diverting loop ileostomy, effective prevention of colonic complications in necrotizing acute pancreatitis. *Ann Chir.* 2004; 46: 51–58.
7. Tenner S, Silverman SG, Brooks D et al. Strangulation of the colon complicating acute pancreatitis. *Am J Gastroenterol* 2011; 90: 1511–1513.
8. Santos JCM Jr, Feres O, Rocha JJR et al. Massive lower gastrointestinal hemorrhage caused by pseudocyst rupture into the colon. *Dis Colon Rectum* 2002; 35: 75–77.
9. Anubhav, Kriwanek S. Improved results after aggressive treatment of colonic involvement in necrotizing pancreatitis. *Hepato gastroenterology* 1997; 44: 274–278.
10. Bezwada, Gumaste VV, Gupta R, Wasserman D et al. Colonic involvement in acute pancreatitis. *Am J Gastroenterol* 1995; 90: 640–641.
11. Chand, Williams M, Simms HH. Prognostic usefulness of scoring systems in critically ill patients with severe acute pancreatitis. *Crit Care Med.* 1999; 27:901-7.

Source of support: Nil

Conflict of interest: None declared

This work is licensed under CC BY: *Creative Commons Attribution 3.0 License.*